

## ZOO 4377L - VERTEBRATE MORPHOLOGY LAB

## LAB 10: CENTRAL NERVOUS SYSTEM

Name: \_\_\_\_\_ SSN: \_\_\_\_\_

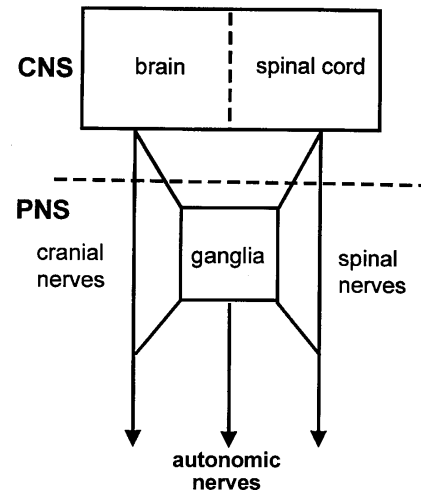
Name: \_\_\_\_\_ SSN: \_\_\_\_\_

Next Week's Assignment: Walker & Homberger - Chapter 10 (Digestive System); read the small print and skim the large print sections

Preparation: Walker & Homberger - pp. 237-258 and 260-282 of Chapter 9 (Nervous System); read the small print and skim the large print sections.

Background

The basic role of nerve cells is to conduct electrical signals from one place to another. The nervous system can be divided *anatomically* into a central nervous system consisting of the brain and spinal cord, and a peripheral nervous system consisting of (1) the nerves projecting from the CNS (cranial and spinal), (2) peripheral collections of neurons known as ganglia, and (3) the nerves emanating from these ganglia. Functionally, the peripheral and central nervous systems are extensively connected. The nervous system is extremely complex, yet its basic structure is highly conserved across vertebrate classes. Two principal cell types compose the nervous system. **Neurons** are responsible for the conducting of neural impulses, but receive support from a second cell type, termed **glia** cells. Both cell types are ectodermal in origin. The brain functions as the organizer and processor of neural impulses. The brain consists largely of nerve cell bodies and unmyelinated fibers that constitute the **gray matter** of the brain. **White matter** is composed of fibers sheathed in myelin which aids in rapid transmission of nerve impulses. Much of the functioning of the brain is poorly understood, but elaborations of particular brain regions corresponds very well with the behaviors characteristic of a group.

Today's Lab

In lab today, we will concentrate primarily on the brain. The lab will consist of three parts: **shark brain dissection**, **sheep brain dissection** and a brief excursion into the bovine **spinal cord** (or human, if available). The shark dissection requires chipping away at the chondrocranium to expose the brain and cranial nerves. The sheep dissection is easier since the brain is already removed from the sheep. We have very little to look at in terms of the spinal cord, so it should not take very long. Once again, the terms are plentiful, but are nearly identical between the shark and sheep. Work to get an understanding of the major functions of each brain region and the cranial nerves associated with them.

In the interests of time, after skinning the shark's head, one member of your dissection team should continue with the shark while the second should start the sheep brain.

In addition to dissection, there are several exhibits to examine. A wet mount comparing the brains of a fish, amphibian, snake, bird and mammal is available. Also available are over-sized models of the brains of the shark, frog, turtle, pigeon, and sheep. You should attempt to identify the five major divisions of the brain (telencephalon, diencephalon, mesencephalon, metencephalon (pons & cerebellum) and myelencephalon (medulla) in each of these craniates and their associated cranial

nerves. Finally, a human brain and cross-section is provided. Again, try to identify the five major divisions and as many cranial nerves as you can.

## I. SHARK BRAIN

Material: Your now familiar shark carcass and preserved chondrocraniums.  
pp. 241-254

Follow Walker & Homberger's directions to dissect the brain on your shark (stop after p. 254). Only the dorsal aspect of the brain will be examined. It requires some care to remove the rather solid chondrocranium without destroying nerve tissue beneath. Refer to the demo dissection to get an idea of how much cartilage needs to be cut away from the head in order to expose the brain and cranial nerves. You may need to refer to the demo dissection again in order to identify all ten cranial nerves. In addition, examine the preserved chondrocranium to get an overall picture of where the brain lies and where nerves exit through foramina (holes in the skull or chondrocranium). Finally, do **not** attempt to remove the brain (thus stop the dissection after p. 254) as it is too soft to remove intact.

Note in skinning the rostrum the translucent canals leading away from the pores in the lateral line system. The little bumps on the internal aspect of the skin at the end of the canals are the actual receptor organs.

Identify: You may want to make a brief description of the following structures to assist in your learning and identification; see Figs. 9-3, 9-4, 9-6, & 9-8. For the next quiz you will be responsible for identifying the structures appearing in **bold**.

**terminal nerve 0**  
**tract of olfactory nerve I**  
**optic nerve II**  
**oculomotor nerve III**  
**trochlear nerve IV**  
**trigeminal nerve V**  
 [abducens nerve VI - not visible dorsally]  
**facial nerve VII**  
**statoacoustic nerve VII (=vestibulocochlear in sheep)**  
**glossopharyngeal nerve IX** - can be difficult to find  
**vagus nerve X**

### Telencephalon

**olfactory sac/bulb**  
**cerebral hemispheres**

### Diencephalon

epiphysis  
 thalamus  
**third ventricle**

### Mesencephalon

**optic lobe**

### Metencephalon

**cerebellum**

### Myelencephalon

**medulla oblongata**  
**fourth ventricle**

## II. SHEEP BRAIN

**Material:** Whole sheep brain,  
sagittal section (demonstration)  
pp. 263-275

The sheep brain is a much easier dissection than the shark. The first step is to demonstrate the 3 layers of the meninges (dura, arachnoid and pia mater). First, identify the 12 cranial nerves by gently peeling the dura and/or arachnoid matter from the ventral surface of the brain (if it has not already been removed). Note that the hypophyseal gland is still attached with its adherent dura mater in both sets. Try to remove the dura without severing the gland, but if this happens, don't worry (be happy). Following identification of the cranial nerves, remove the arachnoid mater from the rest of the brain the identify the 5 regions of the brain and the structures listed in bold for each (see below). Some of these structures can be seen only in sagittal section (indicated by (SS)). When you are ready to make the sagittal section, ask your instructor for help. Note the many differences in surface structure between shark and sheep, but also note the similarity of the brainstem of the sheep and the brain of the shark.

**Read carefully the following instructions:** Following your dissection, complete the table below as it applies to the sheep using Kardong (2002) pp. 616-623 (including Table 16.1) and your dissector. Note that this table has been simplified from the traditional (and outdated) classification of nerve components. Under MOTOR FUNCTION include both both components of somatic motor (general and special (= branchiomeric muscles)) **and generally describe the muscles innervated** (e.g., for CN V the jaw adductors). Ignore general visceral motor. Under SENSORY FUNCTION list indicate the presence / absence (+/-) of general somatic sensory (e.g., touch, temperature, etc.) in the left column and specify any special sensory (either somatic or visceral; e.g., vision, olfaction, etc.) in the right column. Again, do not bother with general visceral sensory. Cranial nerve VII is illustrated.

<u>cranial nerve</u>	<u>Roman numeral</u>	<u>brain region</u>	<u>motor function</u>	<u>sensory function</u>	
				<u>somatic (+/-)</u>	<u>special</u>
olfactory					
optic					
oculomotor					
trochlear					
trigeminal					
abducens					
facial	VII	hindbrain	facial muscle; stylohyoid post. digastric, stapedius	+	taste
vestibulocochlear					
glossopharyngeal					
vagus					
accessory					
hypoglossal					

**Identify:** You may want to make a brief description of the following structures to assist in your learning and identification.

### Meninges

#### **dura mater**

**arachnoid mater** - spans the cerebral fissures

**pia mater** (adherent to brain)

**Telencephalon** (Fig. 9-12, 9-14, 9-18).

**cerebral hemisphere**  
**cerebral fissure**  
**corpus callosum (SS)**  
**lateral ventricles (SS)**  
**tract of olfactory nerve (I)**  
 olfactory bulb  
 piriform bulb

**Diencephalon** (Fig. 9-14, 9-18).

**optic nerve II**  
**thalamus (SS)**  
**epiphysis** (pineal gland) (SS)  
**third ventricle (SS)**

- ? What is the name of the structure where some axons of each optic nerve cross to the opposite side (i.e., decussate)? Examine a ventral view (Fig. 9-8) of the optic nerve in the shark. Is there a similar structure? How do the shark and cat differ in the degree of decussation? What is the relationship between amount of decussation and degree of stereoscopic vision?

**Mesencephalon** (Figs. 9-13, 9-14, 9-18).

**oculomotor nerve III**  
**trochlear nerve IV**  
 cerebral peduncle  
**rostral/superior colliculus**  
**caudal/ inferior colliculus**  
**central canal (SS)**

- ? Note the relative sizes of the superior and inferior colliculus. Which is larger? From this, which sense, vision or hearing, would you think is more acute in sheep?

**Metencephalon** (Fig. 9-12, 9-18).

**trigeminal nerve V**  
**cerebellum**  
 arbor vitae of cerebellum (SS)  
**pons**  
**fourth ventricle (SS)**

**Myelencephalon or medulla oblongata**(Figs. 9-12, 9-14, 9-15, 9-18).

**abducens nerve VI**  
**facial nerve VII**  
**vestibulocochlear nerve VIII**  
**glossopharyngeal nerve IX**  
**vagus nerve X**  
**accessory nerve XI**  
**hypoglossal nerve XII**  
**fourth ventricle (SS)**

### III. SPINAL CORD

Material: Bovine spinal cord section (pp. 281- 282; Figure 9-1)

The vertebrate spinal cord is a dorsal, hollow nerve cord that lies within the neural arches of the vertebral column. Like the brain, the spinal cord is covered by three membranes (the **meninges**), the **dura mater** (outer; L, tough mother), **arachnoid** (middle; G&L, spider- (web-) like mother), and **pia mater** (inner; L, tender mother). The latter is adherent to the spinal cord whereas the arachnoid spans between the **dura** and **pia mater**. Within the spinal cord, **gray matter** (consisting chiefly of neuron cell bodies and having a gray appearance in unfixed material) is arranged in a butterfly-shape at the center and is surrounded by **white matter** (consisting chiefly of axons, most of which are myelinated thus giving a white appearance in unfixed material). The gray matter can be divided into a **dorsal horn** which is primarily sensory in function and a **ventral horn** which is primary motor in function. Projecting to the dorsal horn are **dorsal root** axons whose cell bodies lie in the **dorsal root ganglion** (spinal ganglion). These carry sensory information from receptors in the body to the CNS. Projecting from the ventral horn (from the motoneurons) are the axons of the ventral roots which innervate the smooth (indirectly) and skeletal (directly) muscles of the body. Distal to the meninges the dorsal root and ventral root of each *spinal cord segment* unite to form an individual spinal nerve. Thus, a spinal nerve has both motor and sensory fibers within it. The canal in the center of the spinal cord (rarely visible to the naked eye) is filled with **cerebrospinal fluid**, and is continuous with the brain ventricles. This fluid also circulates around the brain and spinal cord beneath the **arachnoid mater** (i.e., within the sub-arachnoid space) forming a fluid cushion that buffers the central nervous system against shocks.

Using a scalpel make a fresh cut across the rostral and caudal end of a segment of bovine spinal cord. Using a pair of scissors cut the dura mater along the dorsal and ventral midlines for about 2 inches and then extend the cuts laterally. Gently peel back the dura and attempt to identify the **ventral** and **dorsal roots**. The dorsal root ganglia may still be adhered to the dura mater

Identify (Fig. 9-1)

meninges  
**dura mater**  
**arachnoid mater**  
**pia mater** (adherent to spinal cord)  
**gray matter**  
**white matter**  
**ventral horn**  
**dorsal horn**  
**ventral roots**  
**dorsal roots**  
**spinal (dorsal root) ganglion**

- ? Make a sketch of the 2 cut ends of the spinal cord segment and label the **gray matter**, **white matter**, **ventral horn** and **dorsal horn**. Consult your text (Fig. 9-1) and draw in the **ventral roots**, **dorsal roots**, **spinal (dorsal root) ganglion** and **spinal nerve**.
- ? In an isolated piece of spinal cord, how can you distinguish the **dorsal** from the **ventral horns** of the **gray matter**?
- ? If you wanted to remove only sensory innervation of a part of the body, which single structure would you cut?
- ? If you wanted to remove only motor innervation (i.e., paralyze) to a part of the body, which single structure would you cut?